

ORAL MANIFESTATIONS IN CHILDREN WITH GASTROINTESTINAL DISEASES: INTEGRATIVE REVIEW

MANIFESTAÇÕES ORAIS EM CRIANÇAS COM DOENÇAS GASTROINTESTINAIS: REVISÃO INTEGRATIVA

MANIFESTACIONES ORALES EN NIÑOS CON ENFERMEDADES GASTROINTESTINALES: REVISIÓN INTEGRATIVA

Camila Cristine Araújo de Oliveira¹ , Joice Daiane de Oliveira² , Yasmin Dantas de Oliveira¹ , Ana Clara Soares Paiva Torres¹ , Patrícia Bittencourt Dutra dos Santos² , Georgia Costa de Araújo Souza² 

1. Universidade do Estado do Rio Grande do Norte
2. Universidade Federal do Rio Grande do Norte

ABSTRACT

Introduction: Gastrointestinal diseases in children have increased in prevalence and may compromise growth, development and quality of life. Oral manifestations may represent early indicators of these conditions; however, evidence regarding their presentation in pediatric populations remains limited and heterogeneous, hindering robust clinical inferences. **Objective:** To identify oral manifestations in children with gastrointestinal diseases reported in the scientific literature. **Methods:** Integrative review of the literature based on searches of scientific articles at the databases Medline via Pubmed, LILACS, BBO, IBECs, BINACIS, CUMED, LIS, SciELO in 2024. For the search strategy, were used descriptors according to the Health Sciences Descriptor and the Medical Subject Headings system. The inclusion criteria were studies with patients under 15 years of age with gastrointestinal diseases and oral signs, and the exclusion criteria were articles which included patients older than 15 years of age, patients without oral signs, patients without gastrointestinal diseases, non-primary studies, histological and animal studies. Were selected articles published in English, Portuguese or Spanish. **Results:** A total of 16 articles were selected for analysis. Five of which addressed Crohn's disease, 3 inflammatory bowel disease, 7 celiac diseases, 1 Crohn's disease, ulcerative colitis and celiac disease. Oral manifestations associated with gastrointestinal disorders included ulcers (reported in 13 of the 16 articles), enamel defects (7 articles), orofacial edema (6 articles), angular cheilitis (4 articles), cobblestone mucosal appearance (4 articles), and mucosal tags (1 article). **Conclusions:** The available evidence indicates that children with gastrointestinal disorders can present relevant oral manifestations, such as mucosal ulcerations, orofacial edema and enamel defects, which in some cases precede the systemic diagnosis. These steps reinforce the importance of dental examination in early suspicion of systemic diseases in childhood.

Keywords: Oral Manifestations; Gastrointestinal Diseases; Crohn Disease; Celiac Disease; Child.

RESUMO

Introdução: As doenças gastrointestinais em crianças têm aumentado em prevalência e podem comprometer o crescimento, o desenvolvimento e a qualidade de vida. Manifestações orais podem representar indicadores precoces dessas condições; no entanto, as evidências sobre sua apresentação em populações pediátricas permanecem limitadas e heterogêneas, dificultando inferências clínicas robustas. **Objetivo:** Identificar as manifestações orais em crianças com doenças gastrointestinais relatadas na literatura científica. **Métodos:** Revisão integrativa a partir da busca de artigos científicos nas bases de dados Medline via Pubmed, LILACS, BBO, IBECs, BINACIS, CUMED, LIS, SciELO em 2024. Para a estratégia de busca, foram utilizados descritores segundo o Descritor em Ciências da Saúde e o sistema Medical Subject Headings. Os critérios de inclusão foram estudos com pacientes menores de 15 anos com doenças gastrointestinais e sinais orais, e os critérios de exclusão foram artigos que incluíram pacientes maiores de 15 anos, pacientes sem doenças gastrointestinais, pacientes sem sinais orais, estudos não primários, estudos histológicos e com animais. Selecionou-se artigos em inglês, português ou espanhol. **Resultados:** Foram selecionados 16 artigos para análise: 5 sobre doença de Crohn, 3 sobre doença inflamatória intestinal, 7 sobre doença celíaca, e 1 que abordava doença de Crohn, colite ulcerativa e doença celíaca. As manifestações orais dos distúrbios gastrointestinais incluem úlceras (mencionadas em 13 dos 16 artigos), defeitos no esmalte (7 artigos), edema orofacial (6 artigos), queilite angular (4 artigos), fenômeno do paralelepípedo (4 artigos) e marcas na mucosa (1 artigo). **Conclusões:** As evidências disponíveis indicam que crianças com doenças gastrointestinais podem apresentar manifestações orais relevantes, como ulcerações da mucosa, edema orofacial e defeitos do esmalte, que em alguns casos precedem o diagnóstico sistêmico. Esses achados reforçam a importância do exame odontológico na suspeição precoce de doenças sistêmicas na infância.


Correspondência: Georgia Costa de Araújo Souza.
Universidade Federal do Rio Grande do Norte.
Departamento de Odontologia.
georgia_odonto@yahoo.com.br

Recebido: 28/09/2025

Aprovado: 07/03/2026

Publicado: 13/05/2026

Como citar: Oliveira CCA et al. Oral manifestations in children with gastrointestinal diseases: integrative review. Rev. Ciênc. Plural. 2026; 12:e41650. <https://doi.org/10.21680/2446-7286.2026v12n1ID41650>

Editor Associado: Moan Jéfer Fernandes Costa 

Copyright: Este é um artigo de acesso aberto publicado sob uma Licença Creative Commons.



Palavras-chave: Manifestações Oraís; Doenças Gastrointestinais; Doença de Crohn; Doença Celíaca; Criança.

RESUMEN

Introducción: Las enfermedades gastrointestinales en niños han aumentado su prevalencia y pueden comprometer el crecimiento, el desarrollo y la calidad de vida. Las manifestaciones orales pueden ser indicadores tempranos de estas afecciones; sin embargo, la evidencia sobre su presentación en la población pediátrica sigue siendo limitada y heterogénea, lo que dificulta realizar inferencias clínicas sólidas. **Objetivo:** Identificar las manifestaciones orales en niños con enfermedades gastrointestinales reportadas en la literatura científica. **Métodos:** Revisión integrativa de la literatura basada en búsquedas de artículos científicos en las bases de datos Medline (Pubmed), LILACS, BBO, IBECs, BINACIS, CUMED, LIS y SciELO en 2024. Para la estrategia de búsqueda, se utilizaron descriptores según el Descriptor de Ciencias de la Salud y el sistema de Encabezamientos de Temas Médicos. Los criterios de inclusión fueron estudios con pacientes menores de 15 años con enfermedades gastrointestinales y signos orales, y los criterios de exclusión fueron artículos que incluyeran pacientes mayores de 15 años, pacientes sin signos orales, enfermedades gastrointestinales, estudios no primarios, estudios histológicos y estudios en animales. Se seleccionaron artículos publicados en inglés, portugués o español. **Resultados:** Se seleccionaron 16 artículos para su análisis. Cinco de ellos abordaron la enfermedad de Crohn, tres la enfermedad inflamatoria intestinal, siete la enfermedad celíaca, uno la enfermedad de Crohn, colitis ulcerosa y enfermedad celíaca. Las manifestaciones orales asociadas con trastornos gastrointestinales incluyeron úlceras (informadas en 13 de los 16 artículos), defectos del esmalte (7 artículos), edema orofacial (6 artículos), queilitis angular (4 artículos), fenómeno de empedrado (4 artículos) y marcas mucosas (1 artículo). **Conclusiones:** Las evidencias disponibles indican que los niños con enfermedades gastrointestinales pueden presentar manifestaciones orales relevantes, como ulceraciones de la mucosa, edema orofacial y defectos del esmalte, que en algunos casos preceden al diagnóstico sistémico. Estos hallazgos refuerzan la importancia del examen odontológico en la sospecha temprana de enfermedades sistémicas en la infancia.

Palabras clave: Manifestaciones orales; Enfermedades gastrointestinales; Enfermedad de Crohn; Enfermedad celíaca; Niño.

INTRODUCTION

Gastrointestinal diseases are a group of pathologies that can significantly affect children's daily functioning, hinder their educational performance, and impair their overall quality of life, thereby contributing to broader social challenges related to child development and well-being. In recent years, some gastrointestinal diseases have shown an increasing prevalence in child patients, such as food allergy¹, celiac disease and inflammatory bowel disease (IBD)².

These pathologies may, for example, involve permanent intolerance to wheat gluten or related rye and barley proteins in individuals with genetic susceptibility as celiac disease³⁻⁸ or chronic intestinal inflammation, as inflammatory bowel disease, which is divided into Crohn's disease and ulcerative colitis⁹⁻¹². Due to their intestinal and extraintestinal signs and symptoms, a multidisciplinary team with pediatrician, dentist, dermatologist, general surgeon, internist and immunologist¹³ is required.

There is scientific evidence of the relation between systemic health and the oral cavity. As part of the gastrointestinal system, the mouth is easily accessed and can be examined less invasively^{6,14,15}. Oral changes can be signs and symptoms and the first manifestation of a disease in this system which favors early diagnosis and treatment^{14,15}.

Several studies have identified potential associations between specific oral health conditions and gastrointestinal diseases^{3,16-22}. Therefore, understanding how to recognize oral lesions associated with different types of gastrointestinal tract diseases is of paramount importance.

Health professionals must be attentive to oral manifestations and their recurrence, as some mouth conditions can be an indication of a more serious disease that, if treated early, has a chance of cure or treatment that can generate greater well-being for the patient, especially pediatric patients. Therefore, an integrative review specifically focused on the pediatric population is warranted to synthesize existing evidence, identify knowledge gaps, and provide a more structured foundation for clinical practice and future research. Thus, this study aimed to identify in the scientific literature oral manifestations in children with gastrointestinal diseases. according to the Health Sciences Descriptor and the Medical Subject Headings system. The inclusion criteria were studies with patients under 15 years of age with gastrointestinal diseases and oral signs, and the exclusion criteria were articles which included patients older than 15 years of age, patients without oral signs, patients without gastrointestinal diseases, non-primary studies, histological and animal studies. Were selected articles published in English, Portuguese or Spanish.

METHODS

This is an integrative review of the literature with data collected from primary sources. The guiding question was based on the acronym PECO (Population: children; Exposure: gastrointestinal diseases; Comparison: children without gastrointestinal diseases; Outcome: oral manifestations): “What are the oral manifestations in children with gastrointestinal diseases?” The searches were initiated in October 2023 and concluded in March 2024 at the following databases: Medline via Pubmed, LILACS, BBO (Brazilian Dentistry Bibliography), IBECS (Spanish Bibliographic Index of Health Sciences), BINACIS (Argentinian National Bibliography in Health Sciences), CUMED (Centro Nacional de Información de Ciencias Médicas), LIS (Localizador de Informação em Saúde), SciELO (Scientific Eletronic Library Online).

The following descriptors were used to search the articles, according to the Health Sciences Descriptor (DeCS) and the Medical Subject Headings (MeSH) system: Oral Manifestations; Pathology, Oral; mouth diseases; Gastrointestinal Diseases; Gastroesophageal Reflux; Crohn's Disease; Celiac Disease; Colitis, Ulcerative; Inflammatory Bowel Diseases; Child; Child, Preschool; Infant and the combination of three groups of descriptors with the boolean operators AND and OR in all databases (Table 1).

Table 1. Search strategies at the databases of oral manifestations in children with gastrointestinal diseases.

Database	Search strategies
Medline via Pubmed; LILACS; BBO; IBECS; BINACIS; CUMED; LIS; SciELO.	((“Oral Manifestations”) OR (Pathology Oral) OR (“mouth diseases”)) AND (“Gastrointestinal Diseases”) OR (“Gastroesophageal Reflux”) OR (“Crohn Disease”) OR (“Celiac Disease”) OR (Colitis Ulcerative) OR (“Inflammatory Bowel Diseases”)) AND ((Child) OR (Child Preschool) OR (Infant))

Source: Survey data.

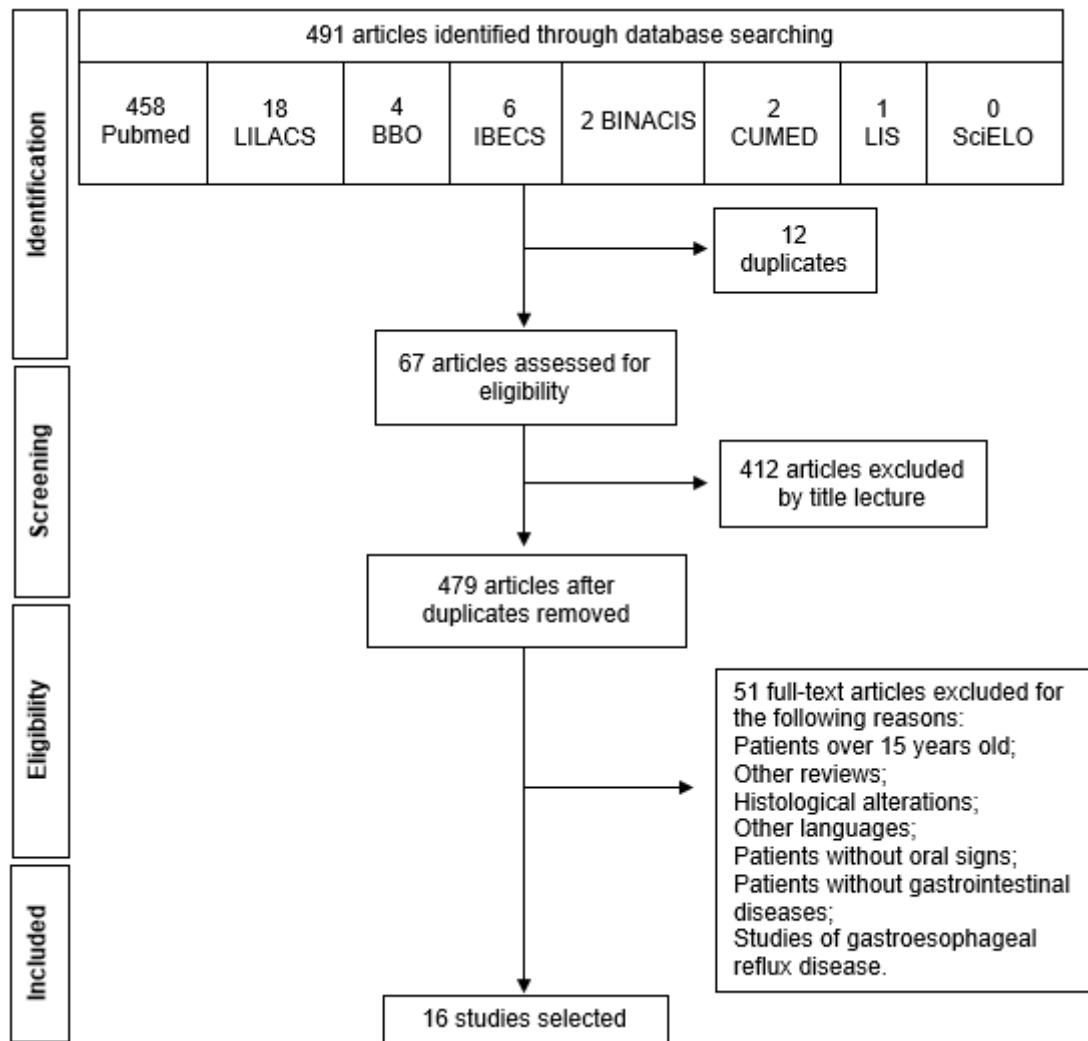
To minimize bias, the search was carried out for all descriptors, and the criteria were defined beforehand by searching the databases. The review stages were carried out by two researchers, in a blind and independent evaluation, following the recommendations from the Preferred Reporting Items for Systematic Reviews and Meta-Analyses (PRISMA)²³. The disagreements were discussed between the reviewers until consensus was reached.

The inclusion criteria were articles published in English, Portuguese or Spanish, which studied gastrointestinal diseases in children up to 15 years of age and which collected information on oral manifestations. There was no limit to publication year. The exclusion criteria were articles which included patients without oral signs, patients without gastrointestinal diseases and case reports, editorials, letters to the editor, other reviews, studies that focused solely on histopathological alterations without clinical correlation, other languages and animal studies.

The selected age group — children and adolescents up to 15 years of age— was chosen because the intestinal microbiota and immune system are still undergoing active development during this period, which significantly influences both the clinical presentation and the systemic impact of gastrointestinal diseases²⁴. In contrast, adolescents older than 15 years often exhibit more autonomous eating habits, behavioral changes, and increased exposure to substances such as ultra-processed foods, alcohol, and tobacco²⁵, all of which may lead to distinct patterns in the epidemiology of gastrointestinal illnesses.

After exclusion of duplicates, the first triage was based on titles, and those not related to oral manifestations in children with gastrointestinal diseases were excluded. The second triage happened after reading the abstracts, and after the exclusions, by full reading (Figure 1).

Figure 1. Flowchart of the selected articles about oral manifestations in children with gastrointestinal diseases.



Source: Survey data.

To assess the prevalence of oral manifestations, the presence of these alterations prior to gluten withdrawal from the diet in cases of celiac disease, and the occurrence of oral lesions before the initiation of anti-inflammatory therapy in cases of inflammatory bowel diseases were considered.

During the study selection process for the analysis of oral manifestations in gastrointestinal diseases, articles addressing gastroesophageal reflux disease were excluded due to the limited number and low representativeness of available studies. This exclusion was implemented to ensure greater methodological consistency and focus on more robust evidence. It is recommended that future research employ specific search strategies for gastroesophageal reflux disease, given the clinical relevance of oral manifestations in this condition.

RESULTS

The search in the databases identified 491 articles and the process of searching and selecting articles is represented in the adaptation of PRISMA flowchart (Figure 1). In this integrative review, 16 articles were included^{5,7,10,26-38}, involving 12 countries with 755 participants aged 0 to 15 years (Table 2). Of these, 4 are case-control, 3 are retrospective, 4 are cohort, 4 are observational and 1 is cohort study. All selected articles were evaluated and information on type of study, gastrointestinal disease and prevalence of oral manifestation was extracted (Table 2).

Table 2. Overview of selected articles on oral manifestations in children with gastrointestinal disorders, including study design, sample size, disease type, and prevalence of oral manifestation.

Authors, Year, Country	Study design (n)	Gastrointestinal Disease	Prevalence Oral manifestation
Scully <i>et al.</i> , 1982, Scotland ⁽²⁹⁾	Observational (n=19)	Crohn's Disease	Labial/facial swelling (84%), mucosal tags/cobblestoning (53%), oral ulceration (42%), angular cheilitis (37%)
Khouri <i>et al.</i> , 2005, Australia ⁽²⁸⁾	Retrospective case series (n=6)	Orofacial granulomatosis evolving into Crohn's Disease	Lip swelling (100%)
Howell <i>et al.</i> , 2012, England ⁽¹⁰⁾	Retrospective (n=24)	Crohn's Disease	Oral ulcers (75%), lip/facial swelling (71%), angular cheilitis (67%), cobblestone phenomenon (67%). In Crohn's Disease: oral ulcers (87%), cobblestone phenomenon (80%) In Orofacial granulomatosis: lip swelling (78%), angular cheilitis (67%).
Gale <i>et al.</i> , 2015, Sweden ⁽²⁶⁾	Cohort (n=10)	Orofacial granulomatosis with or without Crohn's Disease	Orofacial granulomatosis solely: Lip swelling (94%), facial swelling (76%), tag formation (76%), cobblestone phenomenon (76%), angular cheilitis (47%), perioral erythema (35%), ulcer (24%). Orofacial granulomatosis with coexisting Crohn's disease: Lip swelling (83%), facial swelling (92%), tag formation (75%), cobblestone phenomenon (42%), angular cheilitis (42%), perioral erythema (25%), ulcer (8%).
Gale <i>et al.</i> , 2016, Sweden ⁽²⁷⁾	Cohort (n=21)	Crohn's Disease	Orofacial edema (lips) (71%), angular cheilitis (43%), oral ulcers (43%), tag formation (71%), cobblestone phenomenon (28%), perioral erythema (14%) and gingival lesion (19%)
Saalman <i>et al.</i> , 2009, Sweden ⁽³²⁾	Prospective cohort study (n=5)	Crohn's Disease; ulcerative colitis; and Celiac Disease	Orofacial swelling, mucosal edema, ulcerations, mucosal tags (100%); 50% later diagnosed with Crohn's disease
Bucci <i>et al.</i> , 2006, Italy ⁽⁵⁾	Case-control (n=72 CD vs. 162 controls)	Celiac Disease	Dental enamel defects (20% celiac disease vs. 6% controls); recurrent aphthous ulcers (33% CD vs. 23% controls)
Mina <i>et al.</i> , 2012, Argentina ⁽⁷⁾	Follow-up study (n=25 CD vs. 25 controls)	Celiac Disease	Enamel alterations (30%); Aphthous ulcers reported (63%)
Carvalho <i>et al.</i> , 2015, Brazil ⁽³¹⁾	Observational (n=52)	Celiac Disease	Recurrent aphthous ulceration (40% celiac disease vs. 17% controls); and defects in tooth enamel (62% in celiac disease vs. 21% controls); DMFT (2.11 in celiac disease vs. 3.90 controls); low salivary flow (36% in celiac disease vs. 10% controls)
Alamoudi <i>et al.</i> , 2020, Saudi Arabia ⁽³⁰⁾	Observational case-control (n=104 CD vs. 104 controls)	Celiac Disease	Delayed dental maturity: 62% in celiac disease vs. 3% in controls

Moreau et al., 2020, France ⁽³⁸⁾	Case-control (n=28)	Celiac Disease	Defects in tooth enamel (67.9% in celiac disease vs. 33.9% controls); Recurrent aphthous ulceration (50.0% in celiac disease vs. 21.8% controls)
Alsadat et al., 2021, Saudi Arabia ⁽³⁷⁾	Case-control (n=208) (104 celiac disease patients and 104 controls)	Celiac Disease	Recurrent aphthous ulceration (42.3% in celiac disease vs. 15.4% controls); defects in tooth enamel (70.2% in celiac disease vs. 34.6% controls)
Elbek-Cubukcu et al., 2022, Turkey ⁽³⁶⁾	Case-control (n=62 celiac disease vs. 4 controls)	Celiac Disease	Recurrent aphthous ulceration (31% in celiac disease vs. 0% controls); molar-incisor hypomineralization (61% in celiac disease);
Seo et al., 1992, South Korea ⁽³⁴⁾	Observational (n=22)	Inflammatory bowel disease (n=12 Crohn's Disease, n=10 ulcerative colitis)	Oral ulcer (31%)
Ye et al., 2017, China ⁽³⁵⁾	Cohort (n=38)	Inflammatory bowel disease	Oral ulcer (34%)
Angelino et al., 2017, Italy ⁽³³⁾	Retrospective cohort (n=20 Chronic Granulomatous Disease, 9 with Inflammatory Bowel Disease)	Chronic Granulomatous Disease –associated Inflammatory Bowel Disease	Oral aphthosis (1/9; ~11%)

Legend: n = sample number; DMFT = Decayed, Missing and Filled Teeth (mean).
Source: Survey data.

The studies reported a high prevalence of oral manifestations in children with gastrointestinal disorders, particularly in Crohn's disease, orofacial granulomatosis, and celiac disease.

In orofacial granulomatosis (alone or with Crohn's Disease), lip swelling was the most common finding, with prevalence ranging from 78% to 100%; facial swelling and mucosal tag formation were also frequent (75% to 92%); the cobblestone appearance was reported in 28% to 80% of cases; angular cheilitis appeared in up to 67% of patients; oral ulcers varied widely in prevalence, from 8% to 75%, depending on associated conditions.

In Crohn's disease, oral ulcers were highly prevalent, reaching up to 87% of cases. Other frequent features included lip/facial swelling and cobblestone mucosa.

In celiac disease, recurrent aphthous ulceration were significantly more common (31% to 50%) compared to controls (0% to 23%); enamel defects were also significantly more prevalent (62% to 70.2% in celiac disease vs. 6% to 34.6% in controls); other reported findings included delayed dental maturation (62%), low salivary flow (36%), and molar-incisor hypomineralization (61%); interestingly, the DMFT index (Decayed, Missing, and Filled Teeth) was lower in celiac patients (2.11) compared to controls (3.90).

DISCUSSION

The gastrointestinal diseases addressed in this review were Crohn's disease, inflammatory bowel disease, celiac disease, the most frequent investigated in eight studies, and gastroesophageal reflux.

The most common manifestation of IBD was oral ulcer³²⁻³⁵, reported by almost all the studies, followed by edema of oral tissues³². These manifestations can be caused, for example, by a deficit of iron, zinc, or vitamin B12, due to intestinal malabsorption in addition to rectal bleeding related to the main disease, or a pharmacological side effect. Many of the oral changes can be resolved with adequate control of the present intestinal problem³⁹.

Oral ulcerations^{10,26,27,29,34}, orofacial edema^{10,26-28}, cobblestone phenomenon^{10,26-29}, angular cheilitis^{10,26,27,29} and mucosal marks^{26,27,29} are the most prevalent oral manifestations of Crohn's disease. Additionally, there are reports of other oral manifestations, such as perioral erythema and gingival lesions, although only in small samples^{26,27}.

Crohn's disease is often preceded by orofacial granulomatosis (OFG), characterized by edema in the orofacial soft tissues resulting from a granulomatous inflammatory process¹³, with histopathological diagnosis of non-caseous deep granuloma^{10,26,28}, which has orofacial edema, formation of mucosa marks, cobblestone phenomenon and angular cheilitis as clinical signs^{10,26}. Therefore, it is suggested that there is an association between Crohn's disease and OFG, and for this reason, the intraoral clinical examination may indicate the presence of the disease in children with early oral manifestations of OFG²⁸.

The most common oral manifestations of celiac disease were those related to changes in tooth enamel (hypomineralization and hypoplasia)^{5,7,30,31,36-38}. This type of manifestation is associated with the chemical composition of the dental enamel of the patients' teeth with celiac disease who have a lower ratio of calcium (Ca) and phosphorus (P) ions. Regarding the stoichiometry of hydroxyapatite which is the main constituent of enamel, the decrease in the Ca/P ratio can be explained by the incorporation of carbonate in the tissue structure, which increases its solubility. In addition, ion exchange with the environment occurs better in the deeper enamel layers in patients with celiac disease, while under normal conditions it happens in the superficial layers³¹.

The second most cited oral manifestation in studies about celiac disease was recurrent aphthous ulceration (RAU)^{5,31,36-38}. In contrast, in the study of Mina et al.⁷, these ulcerations were not present in the clinical examination, however, most of the sample reported early and continuous occurrence of these manifestations. In addition, 10% of individuals with celiac disease had polymorphonuclear lymphocytes in the cellular composition of the smears of the oral mucosa, which may be related to precipitating factors of RAU⁷.

The explanation for the association between RAU and celiac disease is still unknown, but some hypotheses have been investigated. It may be based on genetic predisposition, being the result of an autoimmune nature, that is, patients who present this condition when exposed to systemic and local factors may have changes in the cells of the oral mucosa, thus causing an uncontrolled action of the defense cells (leukocytes, neutrophils and monocytes).

Another hypothesis suggests that gluten exposure in the oral mucosa of patients with celiac disease could be linked to lymphocyte activity in that area^{40,42}. This suggestion is based on the fact that the oral mucosa and salivary glands are effector sites of the immune system and when they come into contact with gluten, they produce antibodies associated with celiac disease in the oral mucosa of this population^{7,40}. The clinical peculiarity of recurrent aphthous in Celiac disease is its decrease after introducing a gluten-free diet, what needs more study³⁸. However, the high prevalence of RAU in children population could be one explanation for this result⁴⁰.

The findings of this review emphasize the importance of early detection of specific dental and oral mucosa lesions and their association with gastrointestinal diseases. Therefore, dentists, pediatricians and family members should pay special attention to the oral cavity, and have more information on oral manifestations, as early diagnosis of gastrointestinal diseases can prevent their progression and complications³⁶⁻³⁸.

Some limitations of the review should be mentioned. Although we used many combinations and keywords, related articles may have escaped the search. The age limit of children for study selection was 15 years old, so we have many studies excluded. Nevertheless, it is important to highlight that this review was able to gather all or most of the available evidence in the scientific literature on the topic. In order to reduce classification bias, two researchers carried out a blind and independent evaluation, resolving disagreements through consensus. Regarding the selected articles, few studies included control groups in their samples, and the small number of patients enrolled in most of them represents an important limitation of this review. This limitation may be related to the low prevalence of the diseases investigated. Therefore, further research in this area is warranted. Additional studies of this nature, particularly those involving multicenter samples, are recommended, as they could strengthen the findings and enhance the robustness of the available evidence.

CONCLUSION

There is a wide range of oral manifestations of gastrointestinal disorders. Among the most common are oral ulcers, a widely reported change in IBD, Crohn's disease and celiac disease, orofacial edema, angular cheilitis, cobblestone phenomenon, mucosal marks, defects in tooth enamel and dental erosion.

Special attention to the dental surfaces and oral mucosa of children can elucidate the early diagnosis of celiac disease and Crohn's disease. Pediatricians and dentists have a particular importance in the diagnosis, which must include a systematic dental examination, and in the treatment of these manifestations, in order to provide more care and comfort to children.

REFERÊNCIAS

1. Vieira SCF, Santos VS, Franco JM, Nascimento-Filho HM, Barbosa KDOESS, Lyra-Junior DPD, et al. Brazilian pediatricians' adherence to food allergy guidelines—A cross-sectional study. *PLoS one*. 2020;15(2):e0229356. <https://doi.org/10.1371/journal.pone.0229356>
2. Vieira SCF. Adesão de Pediatras às diretrizes para doenças gastrointestinais [doctoral thesis]. Aracaju (SE): Universidade Federal de Sergipe, Brazil; 2019. Disponível em:
3. Acar S, Yetkiner AA, Ersin N, Oncag O, Aydogdu S, Arikan C. Oral findings and salivary parameters in children with celiac disease: A preliminary study. *Med Princ Pract*. 2012;21(2):129–33. <https://doi.org/10.1159/000331794>
4. Aguirre JM, Rodríguez R, Oribe D, Vitoria JC. Dental enamel defects in celiac patients. *Oral Surg Oral Med Oral Pathol Oral Radiol Endod*. 1997;84(6):646–50. [https://doi.org/10.1016/S1079-2104\(97\)90367-X](https://doi.org/10.1016/S1079-2104(97)90367-X)
5. Bucci P, Carile F, Sangianantoni A, D'Angiò F, Santarelli A, Muzio L Lo. Oral aphthous ulcers and dental enamel defects in children with coeliac disease. *Acta Paediatr Int J Paediatr*. 2006;95(2):203–7. <https://doi.org/10.1080/08035250500355022>
6. Campisi G, Compilato D, Iacono G, Maresi E, Di Liberto C, Di Marco V, et al. Histomorphology of healthy oral mucosa in untreated celiac patients: Unexpected association with spongiosis. *J Oral Pathol Med*. 2009;38(1):34–41. <https://doi.org/10.1111/j.1600-0714.2008.00677.x>
7. Mina S, Riga C, Azcurra AI, Brunotto M. Oral ecosystem alterations in celiac children: A follow-up study. *Arch Oral Biol* [Internet]. 2012;57(2):154–60. <http://dx.doi.org/10.1016/j.archoralbio.2011.08.017>
8. Saraceno R, Perugia C, Ventura A, Lorè B, Chimenti S, Docimo R. Aphthous, celiac disease and other dental disorders in childhood. *G Ital Dermatol Venereol*. 2016;151(3):239–43.
9. Harty S, Fleming P, Rowland M, Crushell E, McDermott M, Drumm B, et al. A prospective study of the oral manifestations of Crohn's disease. *Clin Gastroenterol Hepatol*. 2005;3(9):886–91. [https://doi.org/10.1016/s1542-3565\(05\)00424-6](https://doi.org/10.1016/s1542-3565(05)00424-6)
10. Howell JL, Bussell RM, Hegarty AM, Zaitoun H. Service evaluation of patients with orofacial granulomatosis and patients with oral Crohn's disease: Attending a paediatric oral medicine clinic. *Eur Arch Paediatr Dent*. 2012;13(4):191–6. <https://doi.org/10.1007/BF03262869>
11. Hussey S, Fleming P, Rowland M, Harty S, Chan L, Broderick A, et al. Disease outcome for children who present with oral manifestations of Crohn's disease. *Eur Arch Paediatr Dent*. 2011;12(3):167–9. <https://doi.org/10.1007/BF03262800>
12. Pittock S, Drumm B, Fleming P, McDermott M, Imrie C, Flint S, et al. The oral cavity in Crohn's disease. *J Pediatr*. 2001;138(5):767–71. <https://doi.org/10.1067/mpd.2001.113008>
13. Favia G, Limongelli L, Tempesta A, Maiorano E, Capodiferro S. Oral lesions as first clinical manifestations of Crohn's disease in paediatric patients: A report on 8 cases. *Eur J Paediatr Dent*. 2020;21(1):66–9. <https://doi.org/10.23804/ejpd.2020.21.01.13>
14. Kumar KSS, Mungara J, Venumbaka NR, Vijayakumar P, Karunakaran D. Oral manifestations of gastroesophageal reflux disease in children: A preliminary observational study. *J Indian Soc Pedod Prev Dent*. 2018;36(2):125–9. https://doi.org/10.4103/JISPPD.JISPPD_1182_17
15. Mantegazza C, Angiero F, Zuccotti G V. Oral manifestations of gastrointestinal diseases in children. Part 1: General introduction. *Eur J Paediatr Dent*. 2016;17(1):80–2.
16. C Mantegazza, Paglia M, Angiero F, Crippa R. Oral manifestations of gastrointestinal diseases in children. Part 4: Coeliac disease. *Eur J Paediatr Dent*. 2016;17(4):332–4.

17. Chang J, Li CC, Ahtari M, Stoufi E. Crohn's disease initiated with extraintestinal features. *BMJ Case Rep.* 2019;12(4):1–2. <http://dx.doi.org/10.1136/bcr-2019-229916>
18. Crippa R, Zuccotti G V, Mantegazza C. Oral manifestations of gastrointestinal diseases in children. Part 2: Crohn's disease. *Eur J Paediatr Dent.* 2016;17(2):164–6.
19. Dahshan A, Patel H, Delaney J, Wuerth A, Thomas R, Tolia V. Gastroesophageal reflux disease and dental erosion in children. *J Pediatr.* 2002;140(4):474–8. <https://doi.org/10.1067/mpd.2002.123285>
20. Lv H, Qiao B, Fang L, Yang L, Wang Q, Wu S, et al. Neonatal Crohn's disease with Oral ulcer as the first symptom caused by a compound heterozygote mutation in IL-10RA: A case report. *Hereditas.* 2019;156(1):1–10. <https://doi.org/10.1186/s41065-019-0114-8>
21. Mantegazza C, Angiero F, Zuccotti G V. Oral manifestations of gastrointestinal diseases in children. Part 3: Ulcerative colitis and gastro-oesophageal reflux disease. *Eur J Paediatr Dent.* 2016;17(3):248–50.
22. Zoumpoulakis M, Fotoulaki M, Topitsoglou V, Lazidou P, Zouloumis L, Kotsanos N. Prevalence of dental enamel defects, aphthous-like ulcers and other oral manifestations in celiac children and adolescents: A comparative study. *J Clin Pediatr Dent.* 2019;43(4):274–80. <https://doi.org/10.17796/1053-4625-43.4.9>
23. Moher D, Liberati A, Tetzlaff J, Altman DG, Altman D, Antes G, et al. Preferred reporting items for systematic reviews and meta-analyses: The PRISMA statement. *PLoS Med.* 2009;6(7):1–7. <https://doi.org/10.1371/journal.pmed.1000097>
24. Ihekweazu FD, Versalovic J. Development of the pediatric gut microbiome: impact on health and disease. *The American journal of the medical sciences.* 2018; 356(5):413–423. <https://doi.org/10.1016/j.amjms.2018.08.005>
25. Mesas E, Giroto E, Rodrigues R, Martínez-Vizcaíno V, Jiménez-López E, López-Gil JF. Ultra-Processed Food Consumption is Associated with Alcoholic Beverage Drinking, Tobacco Smoking, and Illicit Drug Use in Adolescents: A Nationwide Population-Based Study. *Int J Ment Health Addiction.* 2024; 22(5):3109–3132. <https://doi.org/10.1007/s11469-023-01038-6>
26. Gale G, Östman S, Rekabdar E, Torinsson Naluai A, Högkil K, Hasséus B, et al. Characterisation of a Swedish cohort with orofacial granulomatosis with or without Crohn's disease. *Oral Dis.* 2015;21(1):e98–104. <https://doi.org/10.1111/odi.12236>
27. Gale G, Sigurdsson GV, Östman S, Malmberg P, Högkil K, Hasséus B, et al. Does Crohn's disease with concomitant orofacial granulomatosis represent a distinctive disease subtype'. *Inflamm Bowel Dis.* 2016;22(5):1071–7. <https://doi.org/10.1097/MIB.0000000000000670>
28. Khouri JM, Bohane TD, Day AS. Is orofacial granulomatosis in children a feature of Crohn's disease? *Acta Paediatr Int J Paediatr.* 2005;94(4):501–4. <https://doi.org/10.1111/j.1651-2227.2005.tb01925.x>
29. Scully C, Cochran KM, Russell RI, Ferguson MM, Ghouri MA, Lee FD, et al. Crohn's disease of the mouth: An indicator of intestinal involvement. *Gut.* 1982;23(3):198–201. <https://doi.org/10.1136/gut.23.3.198>
30. Alamoudi NM, Alsadat FA, El-Housseiny AA, Felemban OM, Al Tuwirqi AA, Mosli RH, et al. Dental maturity in children with celiac disease: a case–control study. *BMC Oral Health [Internet].* 2020;20(1):1–10. <https://doi.org/10.1186/s12903-020-01316-y>
31. De Carvalho FK, De Queiroz AM, Bezerra Da Silva RA, Sawamura R, Bachmann L, Bezerra Da Silva LA, et al. Oral aspects in celiac disease children: Clinical and dental enamel chemical evaluation. *Oral Surg Oral Med Oral Pathol Oral Radiol [Internet].* 2015;119(6):636–43. <http://dx.doi.org/10.1016/j.oooo.2015.02.483>
32. Saalman R, Mattsson U, Jontell M. Orofacial granulomatosis in childhood - A clinical entity that may indicate Crohn's disease as well as food allergy. *Acta Paediatr Int J Paediatr.* 2009;98(7):1162–7. <https://doi.org/10.1111/j.1651-2227.2009.01295.x>
33. Angelino G, De Angelis P, Faraci S, Rea F, Romeo EF, Torroni F, et al. Inflammatory bowel disease in chronic granulomatous disease: An emerging problem over a twenty years'

- experience. *Pediatr Allergy Immunol* [Internet]. 2017 Dec;28(8):801–9. <http://doi.wiley.com/10.1111/pai.12814>
34. Seo JK, Yeon KM, Chi JG. Inflammatory bowel disease in children--clinical, endoscopic, radiologic and histopathologic investigation. Vol. 7, *Journal of Korean medical science*. 1992. p. 221–35. <https://doi.org/10.3346/jkms.1992.7.3.221>
 35. Ye Z, Zhou Y, Huang Y, Wang Y, Lu J, Tang Z, et al. Phenotype and Management of Infantile-onset Inflammatory Bowel Disease: Experience from a Tertiary Care Center in China. *Inflamm Bowel Dis*. 2017;23(12):2154–64. <https://doi.org/10.1097/MIB.0000000000001269>
 36. Elbek-Cubukcu C, Arsoy HA, Ozkaya G. Assessment of oral manifestations in pediatric patients with celiac disease in relation to marsh types. *Med Oral Patol Oral Cir Bucal*. 2023 Jan 1;28(1):e9-e15. <https://doi.org/10.4317/medoral.25490>
 37. Alsadat, F. A., Alamoudi, N. M., El-Housseiny, A. A., Felemban, O. M., Dardeer, F. M., & Saadah, O. I. (2021). Oral and dental manifestations of celiac disease in children: a case–control study. *BMC Oral Health*. 2021;21:669. <https://doi.org/10.1186/s12903-021-01976-4>
 38. Moreau, LV, Dicky O, Mas E, Noirrit E, Marty M, Vaysse F, Olives JP. Oral manifestations of celiac disease in French children. *Archives de Pédiatrie*. 2021;28(2):105-110. <https://doi.org/10.1016/j.arcped.2020.11.002>
 39. Lauritano D, Boccalari E, Stasio D Di, Vella F Della, Carinci F, Lucchese A, et al. Prevalence of oral lesions and correlation with intestinal symptoms of inflammatory bowel disease: a systematic review. *Diagnostics*. 2019;9(3):77. <https://doi.org/10.3390/diagnostics9030077>
 40. Rashid M, Zarkadas M, Anca A, Limeback H. Oral manifestations of celiac disease: A clinical guide for dentists. *J Can Dent Assoc (Tor)*. 2011;b39:1-6.
 41. Owczarek-Drabińska JE, Nowak P, Zimoląg-Dydał M, Radwan-Oczko M. The prevalence of oral mucosa lesions in pediatric patients. *Int. J. Environ. Res. Public Health* 2022, 19(18):11277. <https://doi.org/10.3390/ijerph191811277>
 42. Pastore L, Campisi G, Compilato D, Lo Muzio L. Orally based diagnosis of celiac disease: current perspectives. *J Dent Res*. 2008;87(12):1100-7.

Contribuições dos autores: CCAO: Conceitualização, Curadoria de dados, Análise formal, Investigação, Metodologia, Visualização, Redação – rascunho original. JDO: Conceitualização, Curadoria de dados, Análise formal, Investigação, Metodologia, Visualização, Redação – rascunho original. YDO: C Conceitualização, Curadoria de dados, Análise formal, Investigação, Metodologia, Visualização, Redação – rascunho original. ACSPT: Conceitualização, Análise formal, Metodologia, Supervisão, Visualização, Redação – revisão e edição. PBDS: Conceitualização, Análise formal, Metodologia, Supervisão, Visualização, Redação – revisão e edição. GCAS: Conceitualização, Análise formal, Metodologia, Administração do projeto, Supervisão, Visualização, Redação – revisão e edição.

Conflito de interesses: Os autores declaram não haver conflito de interesses.

Financiamento: Não houve financiamento específico para a realização deste estudo.

Disponibilidade de dados: Podem ser disponibilizados mediante solicitação aos autores.

Uso de IA generativa: Os autores declaram que não houve uso de IA generativa no manuscrito.